

## ORIGINAL RESEARCH

# Oral Candidiasis in Human Immunodeficiency Virus Patients and Its Correlation with CD4 Count

Urvashi Tomar<sup>1</sup>, Mamta Singh<sup>2</sup>, Aditee Jhingan<sup>3</sup>, Bhuvnesh Airen<sup>4</sup>, Nikit Agrawal<sup>5</sup>, Priyanka Airen<sup>6</sup>

## ABSTRACT

**Background:** Oral candidiasis is one of the major oral lesions observed in human immunodeficiency virus (HIV) infection. It is linked to the immune suppression with a low CD4 count. The low CD4+ T lymphocyte count poses increased risk to the development of oral candidiasis in these patients. The purpose of this study was to determine the prevalence of oral candidiasis in HIV patients and its correlation with degree of immunosuppression by assessing CD4 count.

**Materials and Methods:** A prospective study was conducted on HIV-positive patients suffering from acquired immunodeficiency syndrome were examined for the presence of Candida infection. The CD4 counts were measured and interrelated with the presence (or absence) of candidiasis.

**Results:** The most common oral lesions were candidiasis (M = 86.6%, F = 71.4%), pigmentation (M = 73.3%, F = 78.5%), and periodontitis (M = 57.7%, F = 42.8%). Other lesions were ulcer, angular cheilitis, and gingivitis. Association of low CD4 count (<200 cells/mm<sup>3</sup> and 0–201 cells/mm<sup>3</sup>) was found with the occurrence of oral candidiasis. Among various forms of oral candidiasis, pseudomembranous candidiasis showed a highly significant association with CD4 counts <200 cells/mm<sup>3</sup>.

**Conclusion:** According to the results, it is found that there is a correlation between occurrence of oral candidiasis and low CD4 count. It can be considered as indicator of the progression of the HIV infection.

**Keywords:** CD4 count, Human immunodeficiency virus positive, Opportunistic infections, Oral Candidiasis.

**How to cite this article:** Tomar U, Singh M, Jhingan A, Airen B, Agrawal N, Airen P. Oral Candidiasis in Human Immunodeficiency Virus Patients and Its Correlation with CD4 Count. *Int J Oral Care Res* 2018;6(1):S31-35.

**Source of support:** Nil

**Conflicts of interest:** None

## INTRODUCTION

Acquired immunodeficiency syndrome (AIDS) is an infectious disease caused by the human immunodeficiency virus (HIV) and is characterized by profound immune suppression that leads to opportunistic infections (OIs), secondary neoplasm, and neurologic manifestations.<sup>[1]</sup> With an HIV epidemic history in the country of more than two decades duration,<sup>[2]</sup> an increase in the number of persons at the advanced stage of disease presenting with medical complications is expected, and this is likely to pose a challenge to the health-care delivery system.

The magnitude of this modern plague is truly staggering. India is one of those countries where the HIV epidemic is growing rapidly. India has the third largest HIV epidemic in the world. In 2016, HIV prevalence in India was an estimated 0.3%. This figure is small compared to most other middle-income countries but because of India's huge population (1.324 billion) this equates to 2.1 million people living with HIV. In the same year, an estimated 62,000 people died from AIDS-related illnesses.<sup>[3]</sup> Nearly 62,000 people death had occurred due to AIDS-related causes.<sup>[4]</sup>

AIDS-associated oral manifestations are common in HIV-positive patients which can reflect the immune status of patients. These oral manifestations can be early signs of the HIV infection in person. The fact that oral lesions can be readily detected by a trained clinician in a standardized, objective fashion without any complicated or expensive diagnostic technique has increased their utility<sup>[5-8]</sup>. The significant findings in AIDS patient are reduced or compromised immunity caused due to inadvertent destruction of circulating CD4-positive T-cell. This often leads to increase in the infections mostly OIs in oral cavity caused by commensal oral microbes. The overall incidence of opportunistic diseases increases with the degree of immunosuppression resulting from HIV disease progression.<sup>[9]</sup>

<sup>1,4,5</sup>Senior Lecturer, <sup>2</sup>Reader, <sup>3</sup>Consultant Dentist, <sup>6</sup>Reader

<sup>1</sup>Department of Oral Pathology, Index Institute of Dental Sciences, Indore, Madhya Pradesh, India

<sup>2,5</sup>Department of Oral and Maxillofacial Surgery, Index Institute of Dental Sciences, Indore, Madhya Pradesh, India

<sup>3</sup>Naval Dental Centre, MI Room, INS Tanaji, Mumbai, Maharashtra, India

<sup>4</sup>Department of Public Health Dentistry, Index Institute of Dental Sciences, Indore, Madhya Pradesh, India

<sup>6</sup>Department of Pedodontics, A.C.P.M. Dental College, Dhule, Maharashtra, India

**Corresponding Author:** Dr. Bhuvnesh Airen, Senior Lecturer, Department of Public Health Dentistry, Index Institute of Dental Sciences, Indore, Madhya Pradesh, India.  
e-mail: bairen69@gmail.com

Oral candidiasis is one of the most common opportunistic oral infections in the presence of decreased immunity as *Candida albicans* is part of oral microbial flora. A number of factors are important in the development of oral candidiasis. However, the level of immunosuppression is vital in the development of oral candidiasis as well as its association with HIV seropositive status of the person. Hence, it is suggested that it can be earliest indicator of reduced immunity or immunosuppression in AIDS.<sup>[10]</sup> However, still, there are different views on the association of CD4-positive T-cell count and appearance of opportunistic lesion such as oral candidiasis, as reduced or depleted CD4-positive T-cell count is associated with a variety of conditions including many viral infections, bacterial infections, parasitic infections, tuberculosis, fungal infection, traumatic conditions, malnutrition, pregnancy, corticosteroid use, normal daily deviation, and psychological stress.<sup>[11]</sup>

With this background, this study was conducted to assess the prevalence of OIs in HIV-infected individuals and its association/correlation with CD4 count.

## MATERIALS AND METHODS

### Study Population

This was a cross-sectional study involving patients with established HIV infection accessing care at the antiretroviral therapy center at Gandhi Medical College, Bhopal, Madhya Pradesh. A total of 83 HIV seropositive patients were screened irrespective of age and sex. Only seropositive patients who have reported for the 1<sup>st</sup> time or have not received any kind of antiretroviral therapy were selected as this may have influence on the presence of oral candidiasis. Any subjects who have received any medicine were excluded from the study.

### Study Design

Detailed clinical and demographic information was obtained, included mode of transmission of disease and presence of oral lesion at time of inclusion along with informed consent.

### Oral Examination

Oral examination was carried out using disposable wooden spatula, gloves, masks, brightly illuminating torch, and sterile pieces of cotton and gauze. The oral lesions associated with HIV infection were diagnosed based on presumptive criteria given by the EC Clearinghouse on oral problems related to HIV infection and the WHO collaborating center on oral manifestations of the HIV [Table 1].<sup>[11]</sup> Oral candidiasis, also

**Table 1:** Revised classification of oral lesions associated with HIV infection (as agreed at a meeting of the EC Clearinghouse on oral problems related to HIV infection, held in London, September 17–18, 1993) [11]

Group 1 lesions strongly associated with HIV infection
Candidiasis
Erythematous
Pseudomembranous
Hairy leukoplakia
Kaposi's sarcoma
Non-Hodgkin's lymphoma
Periodontal disease
Linear gingival erythema
Necrotizing ulcerative gingivitis
Necrotizing ulcerative periodontitis
Group 2 lesion less commonly associated with HIV infection
Bacterial infections
<i>Mycobacterium avium intracellulare</i>
<i>Mycobacterium tuberculosis</i>
Melanotic hyperpigmentation
Necrotizing (ulcerative) stomatitis
Salivary gland disease
Dry mouth due to decreased salivary flow rate
Unilateral or bilateral swelling of major salivary glands
Thrombocytopenic purpura
Ulceration NOS (not otherwise specified)
Viral infection
Herpes simplex virus
Human papillomavirus (wart-like lesion)
Condyloma acuminatum
Focal epithelial hyperplasia
Verruca vulgaris
Varicella zoster virus
Herpes zoster
Varicella
Group 3 lesions shown in HIV infection
Bacterial infections
<i>Actinomyces israelii</i>
<i>Escherichia coli</i>
<i>Klebsiella pneumoniae</i>
Cat scratch disease
Drug reactions (Ulcerative, erythema multiforme, lichenoid, and toxic epidermolysis)
Epithelioid (bacillary) angiomatosis
Fungal infection other than candidiasis
Neurologic disturbances
Facial palsy
Trigeminal neuralgia
Recurrent aphthous stomatitis
Viral infections
Cytomegalovirus
Molluscum contagiosum

familiar as "thrush" or oropharyngeal candidiasis, is a fungal infection that occurs when there is overgrowth of a yeast called *Candida*.

Oral candidiasis comes under Group 1: Lesions strongly associated with HIV infection. Hyperplastic candidiasis has been removed from the classification. Oral candidiasis diagnosis criteria as per EC Clearinghouse were followed in our study:

## Erythematous Candidiasis

Presumptive criteria: Red areas usually located on the palate and dorsum of the tongue, but occasionally on the buccal mucosa. White spots and plaques may be seen, but these are not usually conspicuous.

## Pseudomembranous Candidiasis

### Presumptive criteria

White or yellow spots or plaques that may be located in any part of the oral cavity and can be wiped off to reveal an erythematous surface which may bleed.

## Laboratory Examination

The CD4 T-lymphocyte count of all participants was determined by flow cytometry.

## Statistical Analysis

Patients with oral candidiasis were grouped into four ranges of CD4 cell counts (CDC classification system for HIV infection): <200, 201–300, 301–500, and >500 cells/mm<sup>3</sup>. To study the correlation between the oral candidiasis and CD4-positive T-cell count test was applied.

## RESULTS

A total of 83 patients participated in this study. The age ranged from 20 to 72 years, with a mean age of 33 years. The oral lesions mainly developed in the second and third decade of life [Table 2].

There was a slight male predominance. The predominant mode of transmission of HIV infection was found to be heterosexual contact (81.9%); followed by blood transfusion (3.6%), intravenous drug usage (2.4%), vertical transmission (1.2%), and bisexual contact (1.2%). 8.4% causes were unknown [Table 3]. The prevalence of oral lesions in the present study was found to be 71% ( $n = 59$ ). Large varieties of oral lesions were observed in our study patients [Table 4].

Oral candidiasis (49 [59%]) was found to be the most common oral lesion among the 83 HIV-infected patients. When we compared the different forms of candidiasis, erythematous candidiasis (71.4%) outnumbered other forms of oral candidiasis. This was followed by pseudomembranous candidiasis (28.5%) [Figure 1] and angular cheilitis (22%) [Table 5]. These lesions were Group I lesions most commonly associated with HIV infection, according to EC Clearinghouse criteria [Table 5].

When the presence of oral lesions was correlated with CD4 count, 72% ( $n = 18$ ) presented with candidiasis had CD4 count in range of 0–200 while 28% ( $n = 07$ ) were not having candidiasis. Patients with CD4

count ranging in 201–300 presented with 63% ( $n = 24$ ) cases of candidiasis and 36.8% ( $n = 14$ ) were not having candidiasis. 46% ( $n = 07$ ) patients presented with candidiasis were having CD4 count between 301 and 500 while 53.3% ( $n = 08$ ) were not having candidiasis. Patients having CD4 count >500 were not presented with candidiasis. A statistically significant association was found between occurrences of oral lesions (oral candidiasis) in HIV-positive patients with reduction in CD4 count (<200 cells/mm<sup>3</sup>) ( $P = 0.01$ ) [Table 6]. Melanotic

Table 2: Age and gender distribution of patient

Age group (in years)	Total n (%)	Male n (%)	Female n (%)
<20	04 (4.8)	04 (4.8)	0 (0)
20–30	15 (18)	05 (6)	10 (12)
30–40	39 (46.9)	25 (30)	14 (16.8)
40–50	20 (24)	12 (14.4)	08 (9.6)
>50	05 (6.02)	03 (3.6)	02 (2.4)

Table 3: Mode of infection

Mode of infection	Total n (%)	Male n (%)	Female n (%)
Heterosexual	68 (81.9)	47 (56.6)	21 (25.3)
Homosexual	01 (1.2)	01 (1.2)	00 (0)
IVDU	02 (2.4)	02 (2.4)	00 (0)
Blood transfusion	03 (3.6)	02 (2.4)	01 (1.2)
Vertical transmission	1 (1.2)	00 (0)	01 (1.2)
Needle prick	1 (1.2)	01 (1.2)	00 (0)
Unknown	07 (8.4)	03 (3.6)	04 (4.8)

Table 4: Oral manifestations shown in HIV patients

Lesions	Total n (%)	Male n (%)	Female n (%)
Candidiasis	49 (59)	39 (86.6)	10 (71.4)
Pigmentation	44 (53)	33 (73.3)	10 (78.5)
Periodontitis	32 (38.5)	26 (57.7)	14 (42.8)
Gingivitis	24 (28.9)	16 (35.5)	08 (57.1)
Ulcer	12 (14.4)	05 (11.1)	02 (50)
Angular cheilitis	11 (13.2)	07 (15.5)	04 (28.5)

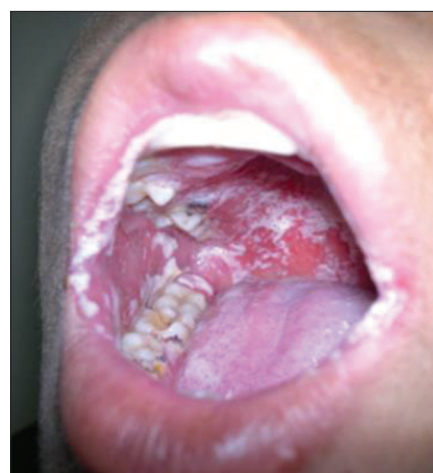

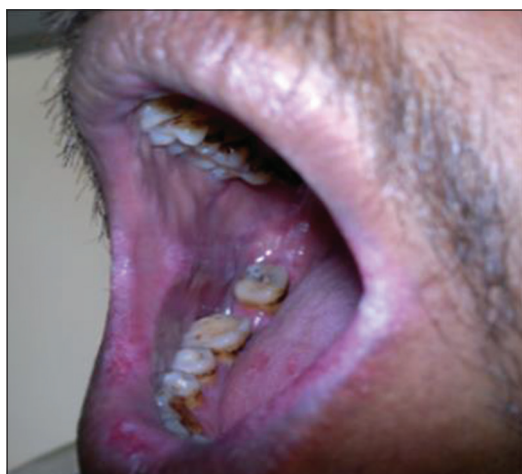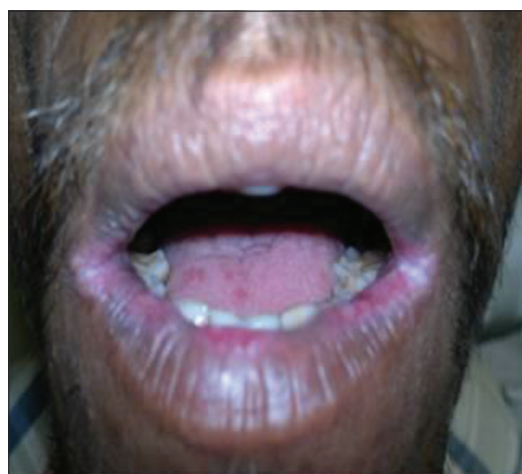
Figure 1: Pseudomembranous candidiasis

**Table 5:** Clinical presentation of oral candidiasis

Lesions	Total n (%)	Male n (%)	Female n (%)	Odds ratio	Confidence interval
Pseudomembranous candidiasis	14 (28.5)	12 (30.7)	02 (71.4)	36.00	4.333–299.03
Erythematous candidiasis	35 (71.4)	27 (69.2)	08 (78.5)	11.390	3.732–34.763
Angular cheilitis	11 (22)	07 (17.9)	14 (42.8)	3.0625	0.539–17.402

**Table 6:** Effect of CD4 on the prevalence of candidiasis

CD4 count (cells/mm <sup>3</sup> )	Number of patients n=83 (%)	Candidiasis present n (%)	Candidiasis absent n (%)
0–200	25 (30.1)	18 (72)	07 (28)
201–300	38 (45.7)	24 (63)	14 (36.8)
301–500	15 (18)	07 (47)	14 (53.3)
>500	05 (6.02)	00 (0)	05 (100)

**Figure 2:** Melanotic hyperpigmentation**Figure 3:** Angular cheilitis

hyperpigmentation (53%) [Figure 2] was found to be the most prevalent oral lesion next to oral candidiasis. This is a Group II lesion which is supposed to be less commonly associated with HIV infection.<sup>[11]</sup> Other lesions in increasing order of their prevalence were ulcers not otherwise specified (14.4%), gingivitis (28.9%), and periodontitis (38.5%) [Figure 3 and Table 4].

## DISCUSSION

HIV causes progressive impairment of the body's cellular immune system, leading to increased susceptibility to tumors, and the fatal condition's known as AIDS.<sup>[12]</sup> The unique feature in the pathogenesis of HIV/AIDS is that the primary target cell for HIV is immune cells bearing CD4 marker at their surface. With the infection of HIV, there is gradual decrease of human immune cells bearing CD4 antigen receptor, the most important being T helper cells (CD4 T cells), B lymphocytes, macrophage, and natural killer cells, leading to the development of wide varieties of OIs, i.e., severe infections induced by agents that rarely cause serious diseases in immune competent individual. In this way, AIDS-related mortality and morbidity, which is significantly higher in number as compared to other diseases, is actually due to OIs rather than HIV itself.<sup>[13]</sup> Oral candidiasis is a commonly described OI globally and has been reported as a marker of immunosuppression. The high incidence of oral candidiasis, especially at low CD4 counts, necessitates the introduction of appropriate intervention for the same.<sup>[14]</sup> CD4 count is the best-validated predictors of likelihood of developing OIs. The CD4 cells coordinate a number of immunological functions, and as these cells are decreased (due to HIV), the risk and severity of OIs increase, resulting in the death of the patients. Hence, CD4 count is an important parameter to initiate OI prophylaxis.<sup>[15]</sup> Some specific, common oral manifestations in HIV infection were found to be associated with immune suppression. These oral disorders may be implicated in the diagnosis and prognosis of HIV-infected patients. We observed that the peak age of occurrence of HIV infection was the second and third decade of life and that there was slight male predilection. This is similar to reported findings from South India<sup>[16,17]</sup> and other parts of the world.<sup>[18-21]</sup> However, a female predominance has been reported mostly in studies in the African region.<sup>[22]</sup> Oral candidiasis is one of the clinical markers of immunosuppression, and antiretroviral therapy should be initiated in patients with persistent oral candidiasis if facilities for performing CD4 counts are not available. In our study, oral candidiasis was the most frequently found oral lesion, which was consistent with many studies.<sup>[5,7,8,12,23]</sup> Among oral candidiasis, the cases of erythematous

candidiasis outnumbered those of pseudomembranous candidiasis. A wide range of oral lesions was reported in the present study. Melanotic hyperpigmentation has been reported to be the second largest lesion associated with HIV infection. Ranganathan *et al.*<sup>[17]</sup> had found it to be the third most common lesion in their study (23%). The possible reasons for occurrence of this pigmentation may be the increased release of  $\alpha$ -melanocyte-stimulating hormone due to deregulated release of cytokines in HIV disease, use of melanocyte-stimulating drugs such as certain antiviral or antifungal agents and Addison's disease. It can be concluded from the present study that oral candidiasis in general; pseudomembranous and erythematous candidiasis specifically are supposed to be good markers of immune suppression than any other oral lesions, as indicated by reduction of the CD4 count  $<200$  cells/mm<sup>3</sup> in patients. Therefore, these oral manifestations may be used as an alternative to CD4 count, with good sensitivity, best specificity, and positive predictive value at field-based settings in developing countries.

## CONCLUSION

According to the above results, it has been concluded that oral surgeons had a good knowledge, positive attitude, and good practices regarding the management of oral cancer and oral precancerous lesions among oral surgeons. Need of more multicentric studies to be conducted to explore the knowledge, attitude, and practice of the surgeons. As this is cross-sectional study conducted only in one city, the results cannot be generalized. Studies to be conducted which shows the factors affecting the management of oral cancer and oral precancerous lesions.

## REFERENCES

1. Abbas AK. Diseases of immunity. In: Kumar V, Abbas AK, Fausto N, Robbins SL, Cotran RS, editors. Robbins and Cotran Pathologic Basis of Diseases. 7<sup>th</sup> ed., Vol. 1. Philadelphia, PA: Saunders; 2004. p. 93-267.
2. Solomon S, Anuradha S, Ganapathy M, Jagadeeswari L. Sentinel surveillance of HIV-1 infection in Tamilnadu, India. *Int J STD AIDS* 1994;6:445-6.
3. National AIDS Control Organization. HIV Sentinel Surveillance technical brief 2016-2017. India: National AIDS Control Organization; 2017.
4. UNAIDS/WHO. Joint United Nations Program on HIV/AIDS. Geneva, Switzerland: UNAIDS DATA; 2017.
5. Hilton JF. Staging the Natural History of HIV Disease. In: Greenspan JS, Greenspan D, editors. Oral Manifestations of HIV Infection. Carol Stream: Quintessence; 1995. p. 42-8.
6. Glick M, Muzyka BC, Lurie D, Salkin LM. Oral manifestations associated with HIV-related disease as markers for immune suppression and AIDS. *Oral Surg Oral Med Oral Pathol* 1994;77:344-9.
7. Margiotta V, Campisi G, Mancuso S, Accurso V, Abbadessa V. HIV infection: Oral lesions, CD4+ cell count and viral load in an Italian study population. *J Oral Pathol Med* 1999;28:173-7.
8. Patton LL. Sensitivity, specificity and positive predictive value of oral opportunistic infections in adults with HIV/AIDS as markers of immune suppression and viral burden. *Oral Surg Oral Med Oral Pathol Oral Radiol Endod* 2000;90:182-8.
9. Salami AK, Olatunji PO, Oluboyo PO. Spectrum and prognostic significance of opportunistic diseases in HIV/AIDS patients in Ilorin, Nigeria. *West Afr J Med* 2006;25:52-6.
10. Samaranyake LP. Oral mycoses in human immunodeficiency virus infection: A review. *Oral Surg Oral Med Oral Pathol* 1992;73:171-80.
11. Clearinghouse EC. Classification and diagnostic criteria for oral lesions in HIV infection. *J Oral Pathol Med* 1993;22:289-91.
12. Cheesbrough M. *District Laboratory Practice in Tropical Countries*. Vol. 2. Cambridge: University Press; 2007. p. 253-65.
13. Madigan MT, Martinko JM, Parker J. *Brock Biology of Microorganisms*. 11<sup>th</sup> ed. Upper Saddle River (USA): Prentice Hall; 2006. p. 875-84.
14. Sharma G, Pai KM, Suhas S, Ramapuram JT, Doshi D, Anup N. Oral manifestations in HIV/AIDS infected patients from India. *Oral Dis* 2006;12:537-42.
15. Sharma S, Dhungana GP, Pokhrel BM, Rijal BP. Opportunistic infections in relation to CD4 level among HIV seropositive patients from central Nepal. *Nepal Med Coll J* 2010;12:1-4.
16. Ranganathan K, Reddy BV, Kumarasamy N, Solomon S, Viswanathan R, Johnson NW. Oral lesions and conditions associated with human immunodeficiency virus infection in 300 South Indian patients. *Oral Dis* 2002;6:152-7.
17. Ranganathan K, Umadevi M, Saraswathi TR, Kumarasamy N, Solomon S, Johnson N. Oral lesions and conditions associated with human immunodeficiency viral infection in 1000 South Indian patients. *Ann Acad Med Singapore* 2004;33:37-42.
18. Ramirez V, Gonzalez A, de la Rosa E, Gonzalez M, Rivera I, Hernandez C, *et al.* Oral lesions in Mexican HIV-infected patients. *J Oral Pathol Med* 1990;19:482-5.
19. Schulten EA, ten Kate RW, van der Waal I. Oral manifestations of HIV infection in 75 Dutch patients. *J Oral Pathol Med* 1989;18:42-6.
20. Moniaci D, Greco D, Flecchia G, Raiteri R, Sinicco A. Epidemiology, clinical features and prognostic value of HIV-1 related oral lesions. *J Oral Pathol Med* 1990;19:477-81.
21. Anil S, Challacombe SJ. Oral lesions of HIV and AIDS in Asia: An overview. *Oral Dis* 1997;3:36-40.
22. Tukutuku K, Muyembe-Tamfum L, Kayembe K, Odio W, Kandi K, Ntumba M. Oral manifestations of AIDS in a heterosexual population in a Zaire hospital. *J Oral Pathol Med* 1990;19:232-4.
23. Kerdpon D, Pongsiriwet S, Pangsomboon K, Iamaroon A, Kampook K, Sretrirutchi S, Geater A, Robinson V. Oral manifestations of HIV infection in relation to clinical and CD4 immunological status in northern and southern Thai patients. *Oral Dis* 2004;10:138-44.